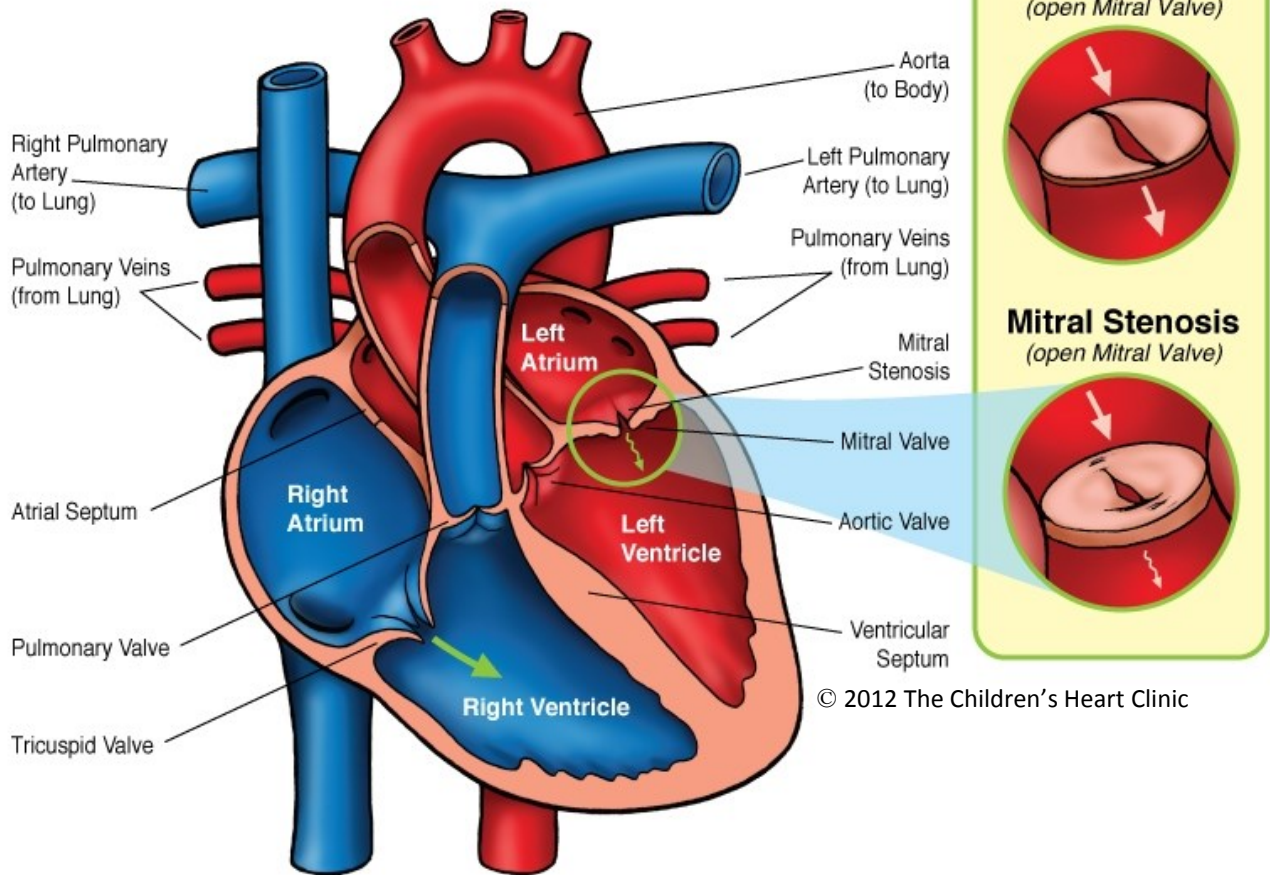


Mitral Stenosis



NOTES:

Children's Heart Clinic, P.A., 2530 Chicago Avenue S, Ste 500, Minneapolis, MN 55404
 West Metro: 612-813-8800 * East Metro: 651-220-8800 * Toll Free: 1-800-938-0301 * Fax: 612-813-8825
 Children's Minnesota, 2525 Chicago Avenue S, Minneapolis, MN 55404
 West Metro: 612-813-6000 * East Metro: 651-220-6000

Mitral Stenosis (MS)

Mitral stenosis (MS) refers to narrowing of the mitral valve. This narrowing prevents the mitral valve from opening properly, which leads to restriction of blood flow from the left atrium to the left ventricle and out to the body. MS is usually associated with other congenital heart defects, such as Shone's syndrome. Obstruction may be present at the level of the valve leaflets, papillary muscle, the chordate, and/or the supralvalvar region (supralvalvar mitral ring). The valve annulus itself may be quite hypoplastic (underdeveloped), leading to stenosis. Commonly, obstruction is present at more than one level in congenital MS. MS as a result of rheumatic fever is more common in adults, but rare for infants or children. In rheumatic MS, the valve leaflets are thickened and commissures become fused and calcified over time, leading to immobility of the valve. Mitral stenosis may also occur if the patient has had bacterial endocarditis. Regardless of the cause, obstruction of the mitral valve leads to left atrial hypertrophy (enlargement), pulmonary venous and arterial hypertension (elevated pressure) with resulting right-sided hypertrophy.

Physical Exam/Symptoms:

- Children with mild MS are asymptomatic (no symptoms).
- In severe MS, infants develop respiratory distress, poor growth and development early.
- Older children with moderate to severe MS develop dyspnea (difficulty breathing) with or without exertion.
- Neck vein distension occurs with right-sided heart failure.
- Loud first and second heart sounds, ejection click, and opening snap may be auscultated.
- Pulmonary regurgitation murmur may be present with long-standing pulmonary hypertension.
- Atrial fibrillation is rare in children, but may occur.

Diagnostics:

- Chest X-ray: Enlargement of the right ventricle and left atrium and prominent main pulmonary artery segment is often present. Pulmonary venous congestion and interstitial edema are usually seen.
- EKG: Left atrial hypertrophy, right ventricular hypertrophy, and right axis deviation are common.
- Echocardiogram: Diagnostic.

Medical Management/Treatment:

- Mild to moderate MS is managed with medications, such as diuretics (Lasix).
- Infants with severe MS may undergo balloon dilation of the mitral valve in the catheterization lab in an effort to delay surgical intervention and allow time for growth.
- Bacterial endocarditis (SBE) prophylaxis prior to dental procedures.
- Patients with MS resulting from rheumatic fever should be on antibiotic prophylaxis to prevent recurrence.
- Surgical repair or replacement of the mitral valve is often warranted for patients with symptomatic congenital MS or asymptomatic children with elevated pulmonary artery pressures (see Mitral Valve Replacement).
- Children with a mechanical mitral valve will require Coumadin and Aspirin for anticoagulation.
- Life-long cardiology follow-up every 6-12 months following repair or replacement of the mitral valve.

Long-Term Outcomes:

- Children with congenital mitral stenosis that go untreated have a high mortality rate, with a mean survival to 3 years of age.
- Long-term outcomes vary depending on mitral valve function and other co-morbidities.
- The need for re-operation on the mitral valve is not uncommon.
- Bacterial endocarditis prophylaxis is required in patient who've had a mitral valve replacement.