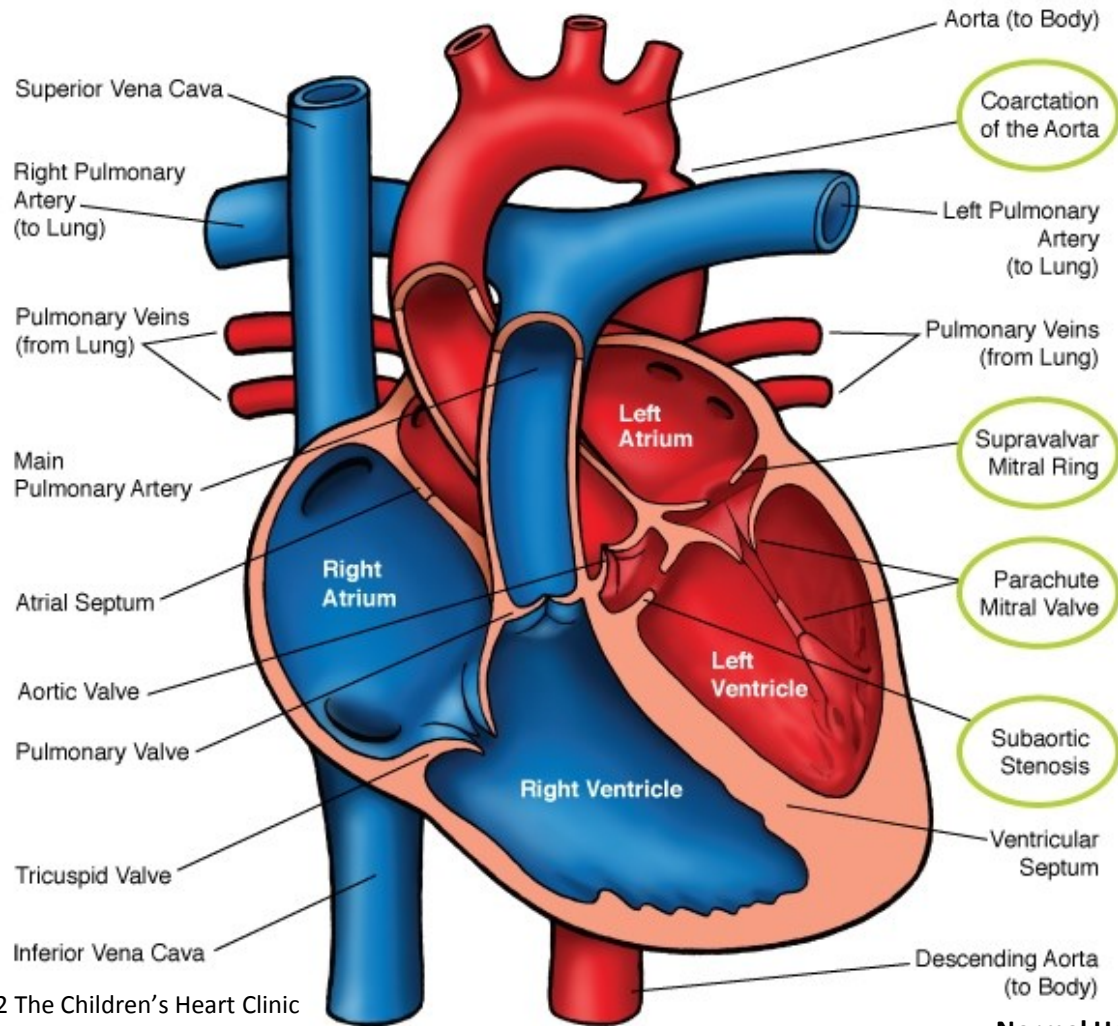
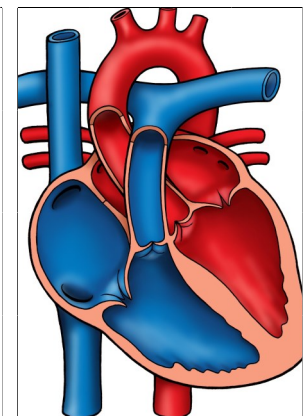


Shone's Syndrome



© 2012 The Children's Heart Clinic

Normal Heart



NOTES:

Children's Heart Clinic, P.A., 2530 Chicago Avenue S, Ste 500, Minneapolis, MN 55404

West Metro: 612-813-8800 * East Metro: 651-220-8800 * Toll Free: 1-800-938-0301 * Fax: 612-813-8825

Children's Minnesota, 2525 Chicago Avenue S, Minneapolis, MN 55404

West Metro: 612-813-6000 * East Metro: 651-220-6000

Shone's Syndrome

Shone's syndrome (also known as Shone's complex) is a rare combination of four left-sided congenital cardiac anomalies including parachute mitral valve, supralvalvar mitral ring, coarctation (narrowing) of the aorta, and subaortic obstruction. The mitral valve leaflets are abnormal, often thickened or immobile with fused commissures and thick, shortened chords, giving the valve a "parachute" shape. Mitral regurgitation (leaking of blood back through the mitral valve) and stenosis (narrowing of the mitral valve) are characteristic of Shone's syndrome.

Supralvalvar rings are made up of an abnormal ridge of connective tissue that obstructs blood flow through the mitral valve. Coarctation of the aorta prevents adequate blood flow from getting out of the left ventricle to the body. Subaortic obstruction due to narrowing of the left ventricular outflow tract may be worse if thickened papillary muscles are present. These left-sided heart problems and associated symptoms get worse over time without treatment. Shone's syndrome occurs in less than 1% of all congenital cardiac anomalies.

Physical Exam/Symptoms:

- Symptoms of congestive heart failure: fatigue, tachypnea (fast breathing), tachycardia (fast heart rate), poor weight gain, and edema (fluid retention).
- Loud first and second heart sounds, ejection click and opening snap may be auscultated.
- Pulmonary regurgitation murmur may be present with long-standing pulmonary hypertension.

Diagnostics:

- Chest X-ray: Cardiomegaly due to enlargement of the right ventricle and left atrium. Pulmonary vasculature is prominent and pulmonary edema is present.
- EKG: Left atrial hypertrophy, right ventricular hypertrophy, and right axis deviation are common.
- Echocardiogram: Diagnostic.
- Cardiac Catheterization or Computed Tomography Angiogram

Medical Management/Treatment:

- For infants that are diagnosed prenatally with Shone's syndrome, it is recommended that delivery take place in a tertiary care hospital with transfer to the Neonatal Intensive Care Unit as soon as possible to initiate cardiology evaluation and medical interventions.
- When coarctation is present, prostaglandin E infusion is started as soon as possible to keep the ductus arteriosus open prior to surgery.
- Surgical intervention shortly after birth to repair coarctation of the aorta is usually necessary.
- Multiple surgical interventions may be needed to relieve left-sided obstructions.
- Medications may be needed to treat symptoms of congestive heart failure and/or pulmonary hypertension.
- Bacterial endocarditis antibiotic prophylaxis is required prior to any dental procedures.
- Life-long cardiology follow up is needed.

Long-Term Outcomes:

- Infants with significant coarctation who do not undergo surgical intervention usually do not survive.
- Pulmonary hypertension may be a chronic problem requiring medications to manage.
- Growth and developmental outcomes vary depending on severity of disease and the presence or absence of other co-morbidities.