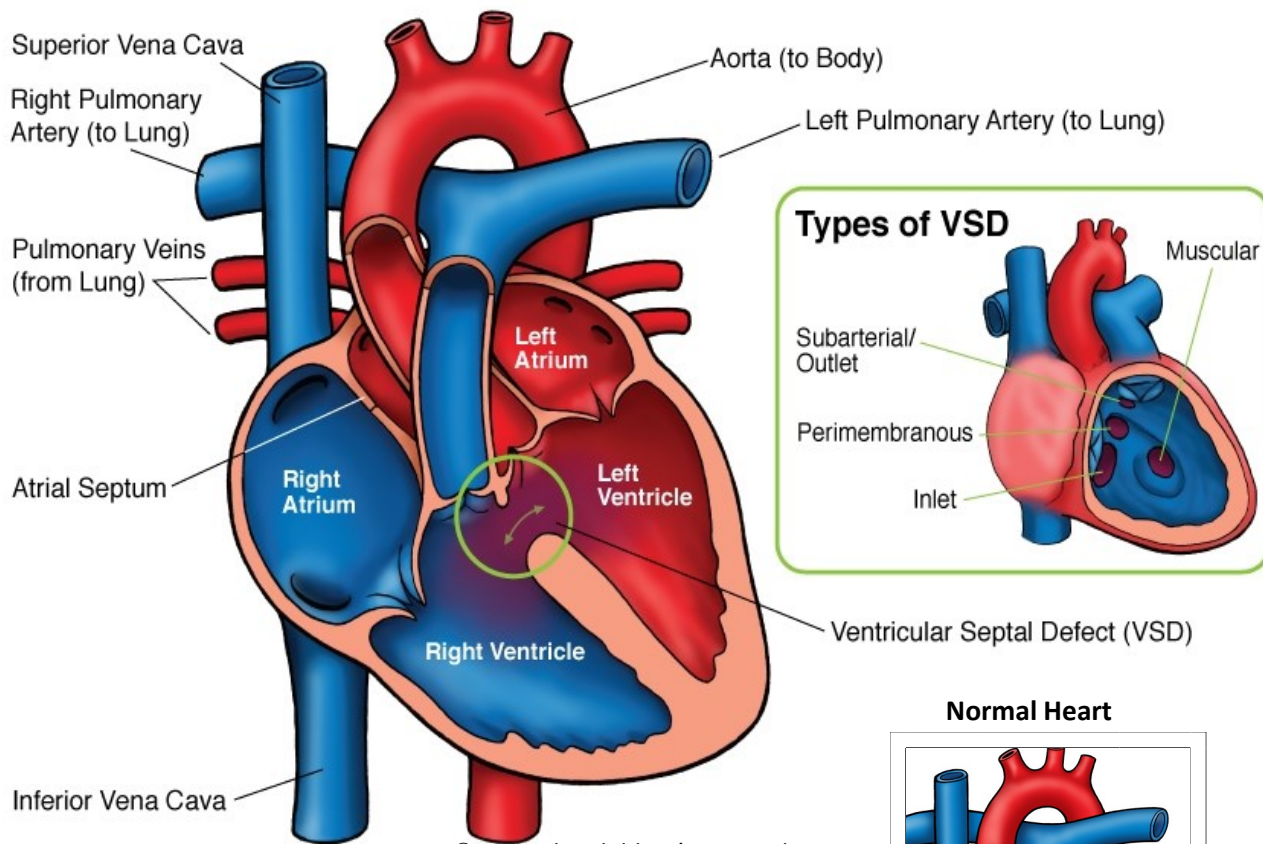


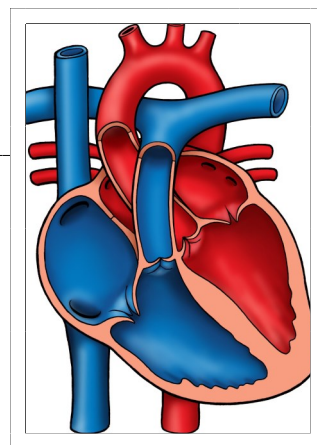
Ventricular Septal Defect (VSD)



© 2012 The Children's Heart Clinic



NOTES:



Children's Heart Clinic, P.A., 2530 Chicago Avenue S, Ste 500, Minneapolis, MN 55404
 West Metro: 612-813-8800 * East Metro: 651-220-8800 * Toll Free: 1-800-938-0301 * Fax: 612-813-8825
 Children's Minnesota, 2525 Chicago Avenue S, Minneapolis, MN 55404
 West Metro: 612-813-6000 * East Metro: 651-220-6000

Ventricular Septal Defect (VSD)

A ventricular septal defect (VSD) is a hole between the lower two chambers of the heart (ventricles). VSDs are the most common type of congenital heart disease (20% of all cardiac defects). VSDs may also occur in conjunction with other heart defects. There are several types of VSDs, classified by their location on the ventricular septum.

Types:

- **Perimembranous:** Located beneath the aortic valve. These are the most common type of VSD (70%).
- **Outlet (infundibular or conal):** Located within the outlet (conal) septum. Part of the rim of this VSD comprises the pulmonary and aortic annulus. Outlet VSDs account for 5-7% of VSDs.
- **Inlet (AV canal):** Located posterior and inferior to the perimembranous defect, below the tricuspid valve septal leaflet. Inlet VSDs account for 5-8% of VSDs.
- **Muscular (Trabecular):** Midmuscular VSDs are located posterior to the septal band. Apical muscular defects are located near the cardiac apex. Some patients have multiple muscular VSDs present. This type accounts for 5-20% of all VSDs.

Physical Exam/Symptoms:

- Children with small VSDs are asymptomatic. A regurgitant systolic murmur is heard best at the left lower sternal border. A systolic thrill may be palpable. The intensity of the murmur does not reflect the size or degree of symptoms.
- Large VSDs may be associated with delayed growth and development, symptoms of pulmonary infections, exercise intolerance, and poor feeding. Symptoms of congestive heart failure usually develop within 6-8 weeks of age in children with large VSDs. Pulmonary hypertension may also occur.
- Older children with unrecognized large VSDs may have cyanosis (blue color) and clubbing as a result of pulmonary obstructive disease (Eisenmenger's syndrome).

Diagnostics:

- **Chest X-ray:** Varying degrees of cardiomegaly (enlarged heart) is present with increased pulmonary vascular markings relative to the amount of left to right shunting.
- **EKG:** Evidence of left atrial and/or left ventricular enlargement.
- **Echocardiogram:** Diagnostic.

Medical Management/Treatment:

- 30-40% of *muscular and membranous* VSDs close within the first 6 months or become smaller with age. *Inlet and outlet* VSDs do not close spontaneously or get smaller with age.
- Medications such as diuretics (Lasix) and ACE inhibitors (enalapril, captopril), and/or high-calorie formula/fortified breast milk may be used to allow time for spontaneous closure or to delay surgical treatment.
- VSDs can be closed surgically (see [VSD repair](#)). Some muscular VSDs may be closed with a device in the catheterization lab.
- Cardiology follow up is recommended through childhood.
- No activity restrictions or long-term medications are needed for children who have spontaneous closure or surgical repair of their VSDs in the absence of other heart disease.

Long-Term Outcomes:

- Normal life expectancy
- Bacterial endocarditis prophylaxis is discontinued 6 months after closure/repair if no residual shunt/cardiac lesion.