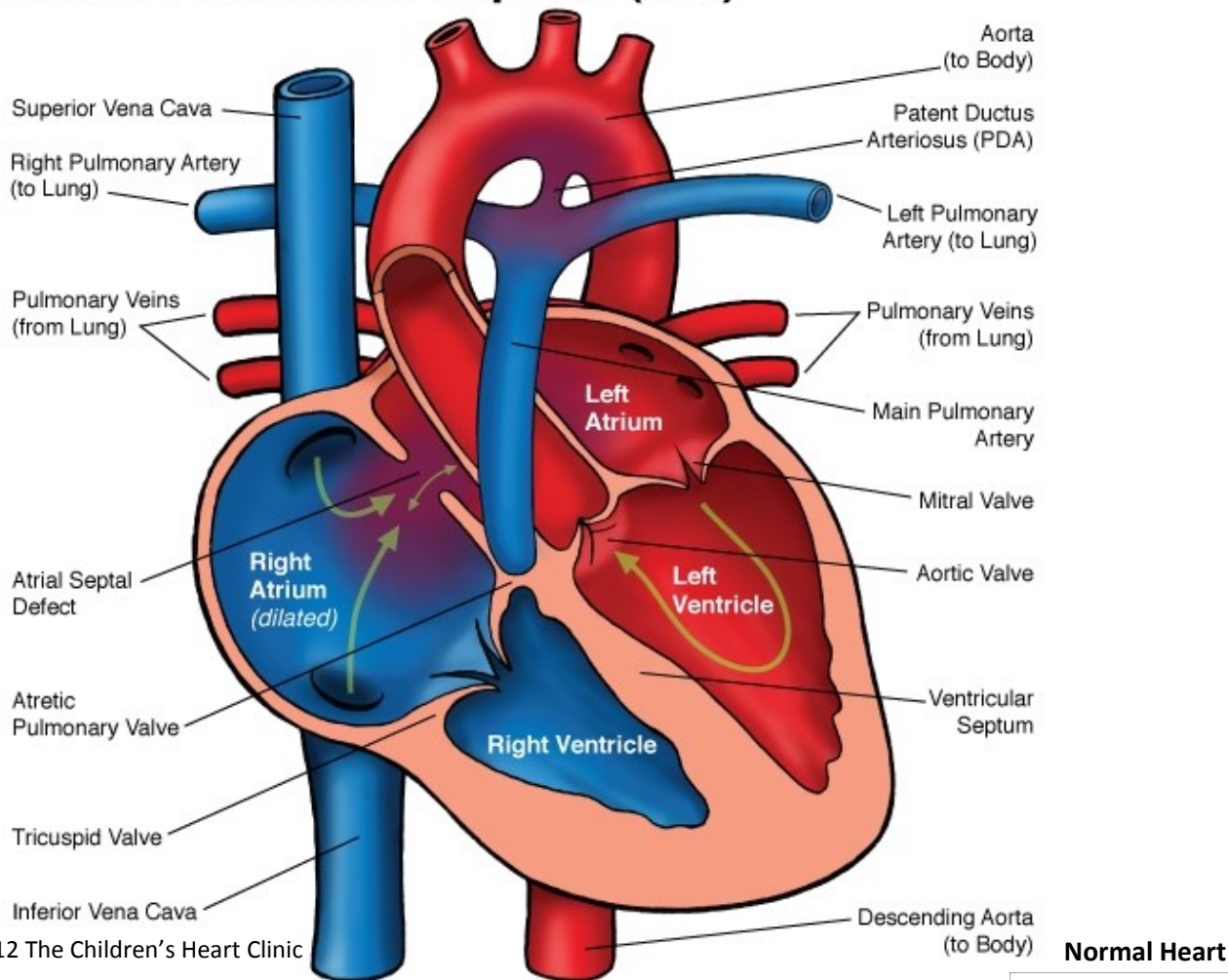


## Pulmonary Atresia Intact Ventricular Septum (IVS)

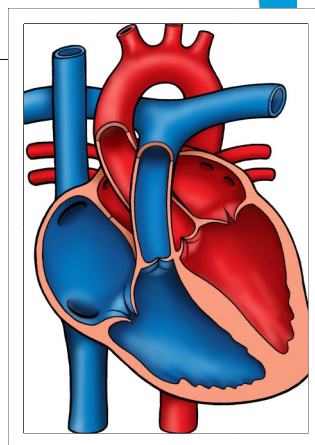


© 2012 The Children's Heart Clinic

**Normal Heart**



**NOTES:**



Children's Heart Clinic, P.A., 2530 Chicago Avenue S, Ste 500, Minneapolis, MN 55404  
 West Metro: 612-813-8800 \* East Metro: 651-220-8800 \* Toll Free: 1-800-938-0301 \* Fax: 612-813-8825  
 Children's Minnesota, 2525 Chicago Avenue S, Minneapolis, MN 55404  
 West Metro: 612-813-6000 \* East Metro: 651-220-6000

---

## Pulmonary Atresia with Intact Ventricular Septum (PA/IVS)

Pulmonary atresia with intact ventricular septum (PA/IVS) refers to the absence or underdevelopment of the pulmonary valve and the absence of a communication between the lower two chamber of the heart (ventricles). The pulmonary valve ring and main pulmonary artery are hypoplastic (underdeveloped) due to lack of blood flow in utero. This means there is no direct communication between the right ventricle and the pulmonary artery. The only source of blood to the lungs is supplied by a patent ductus arteriosus (PDA), a normal fetal structure that usually closes in the first week of life. PA/IVS is often associated with coronary anomalies, such as obstruction or absence of the proximal or left coronary artery. The right ventricle (RV) size varies and portions of the right ventricle may be absent. The muscle (myocardium) of the right ventricle (RV) is often abnormal. PA/IVS accounts for less than 1% of all congenital heart defects and 2.5% of all critically ill infants with congenital heart disease.

### Physical Exam/Symptoms:

- Severe cyanosis (blue color) persists from birth.
- Tachypnea is often present.
- Heart murmur is usually not present, although a soft continuous murmur of the PDA may be heard. There is a single S2 heart sound, as the pulmonary valve does not close normally.

### Diagnostics:

- Chest X-ray: Heart size ranges from normal to enlarged, depending on right atrial size. Pulmonary vascular markings are diminished due to lack of blood flow to the lungs.
- EKG: Left ventricular and right atrial enlargement is common. The QRS axis is normal.
- Echocardiogram: Diagnostic.

### Medical Management/Treatment:

- Prostaglandin E infusion started at birth or as soon as diagnosis is suspected to keep the ductus arteriosus open for pulmonary blood flow.
- Cardiac catheterization preoperatively to evaluate the right ventricular size and coronary arteries.
- Occasionally, a balloon atrial septostomy is required to increase right to left shunting of blood if the right ventricle is too small for biventricular surgical repair.
- Surgery is always indicated. The type of surgical procedure depends on the size of the right ventricle and the presence or absence of coronary sinusoids or abnormalities.
- Bacterial endocarditis prophylaxis is indicated prior to any dental procedures.
- Life-long cardiology follow-up/management.

### Long-Term Outcomes:

- Without surgical intervention, there is an 80% mortality by age 6 months.
- Life-expectancy and developmental outcomes vary widely depending on cardiac physiology, surgical outcome, and the presence or absence of other co-morbidities.