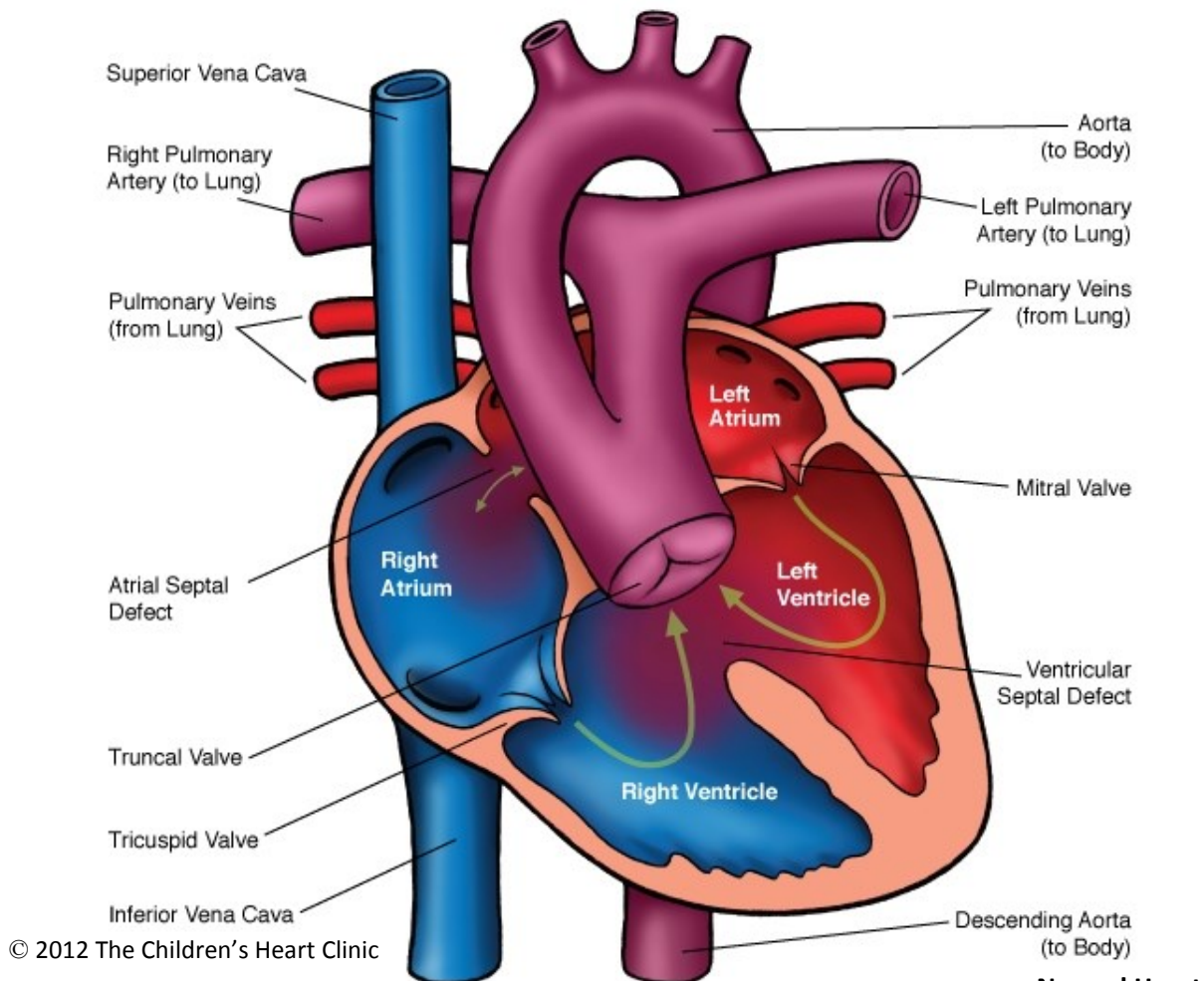
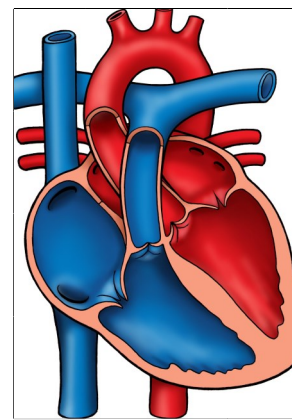


## Truncus Arteriosus



### NOTES:

### Normal Heart



Children's Heart Clinic, P.A., 2530 Chicago Avenue S, Ste 500, Minneapolis, MN 55404  
 West Metro: 612-813-8800 \* East Metro: 651-220-8800 \* Toll Free: 1-800-938-0301 \* Fax: 612-813-8825  
 Children's Minnesota, 2525 Chicago Avenue S, Minneapolis, MN 55404  
 West Metro: 612-813-6000 \* East Metro: 651-220-6000

---

## Truncus Arteriosus

Truncus arteriosus is a rare congenital heart defect in which a single arterial blood vessel (truncus) gives rise to the systemic, pulmonary, and coronary circulations. The pulmonary arteries arise from the ascending aorta. There is a single truncal valve with two, three, or four leaflets. It is often incompetent, resulting in regurgitation (backflow of blood). A large perimembranous ventricular septal defect (VSD) is present directly below the truncus in all cases. This allows for mixing of the pulmonary and systemic venous blood and equal pressures in both ventricles. The magnitude of pulmonary blood flow (PBF) is determined by the size of the pulmonary artery. If PBF is excessive, congestive heart failure (CHF) may occur as a result of volume overload placed on the ventricle. If PBF is small, the infant may appear more cyanotic (blue) with no CHF symptoms.

The coronary arteries are frequently abnormal. 30% have a right aortic arch and 33% of individuals with truncus have DiGeorge syndrome. Most infants present with cyanosis or symptoms of CHF within the first two weeks of life if not diagnosed prenatally. Truncus arteriosus occurs in less than 1% of congenital heart defects.

### Physical Exam/Symptoms:

- Varying degrees of cyanosis and signs of CHF are usually present, including dyspnea (difficulty breathing), tachycardia (fast heart rate), difficulty feeding, and failure to thrive (FTT).
- Frequent respiratory infections are common.
- Bounding peripheral pulses and a wide pulse pressure are present.
- Hyperactive precordium and laterally displaced apical impulse.
- An early diastolic murmur of truncal regurgitation may be heard. Occasionally, a harsh, regurgitant systolic VSD murmur may be heard along the left sternal border. A systolic click may be heard at the apex and upper left sternal border and S2 is single. If pulmonary blood flow is excessive, an apical diastolic rumble with or without gallop rhythm may be present.

### Diagnostics:

- Chest X-ray: Cardiomegaly (enlarged heart) with increased pulmonary vascular markings.
- EKG: Normal QRS axis. Biventricular hypertrophy is present in 70% of children.
- Echocardiogram: Diagnostic.

### Medical Management/Treatment:

- Bacterial prophylaxis is recommended prior to any dental procedure.
- Anticongestive medications, such as diuretics (Lasix), are often needed for symptom management prior to surgical repair.
- Chromosome analysis should be done shortly after birth due to frequent association with DiGeorge syndrome.
- Surgical repair occurs most often in the first week of life (see Rastelli procedure).
- Life-long cardiology follow up is needed.
- Cardiac catheterization for balloon dilation or stent placement in the right ventricle to pulmonary artery conduit or percutaneous valve placement may be needed in the future to increase the longevity of the conduit.
- Surgical replacement of the right ventricle to pulmonary artery conduit will be required due to normal growth of the child or calcification of the conduit.
- Participation in competitive contact sports is not recommended.