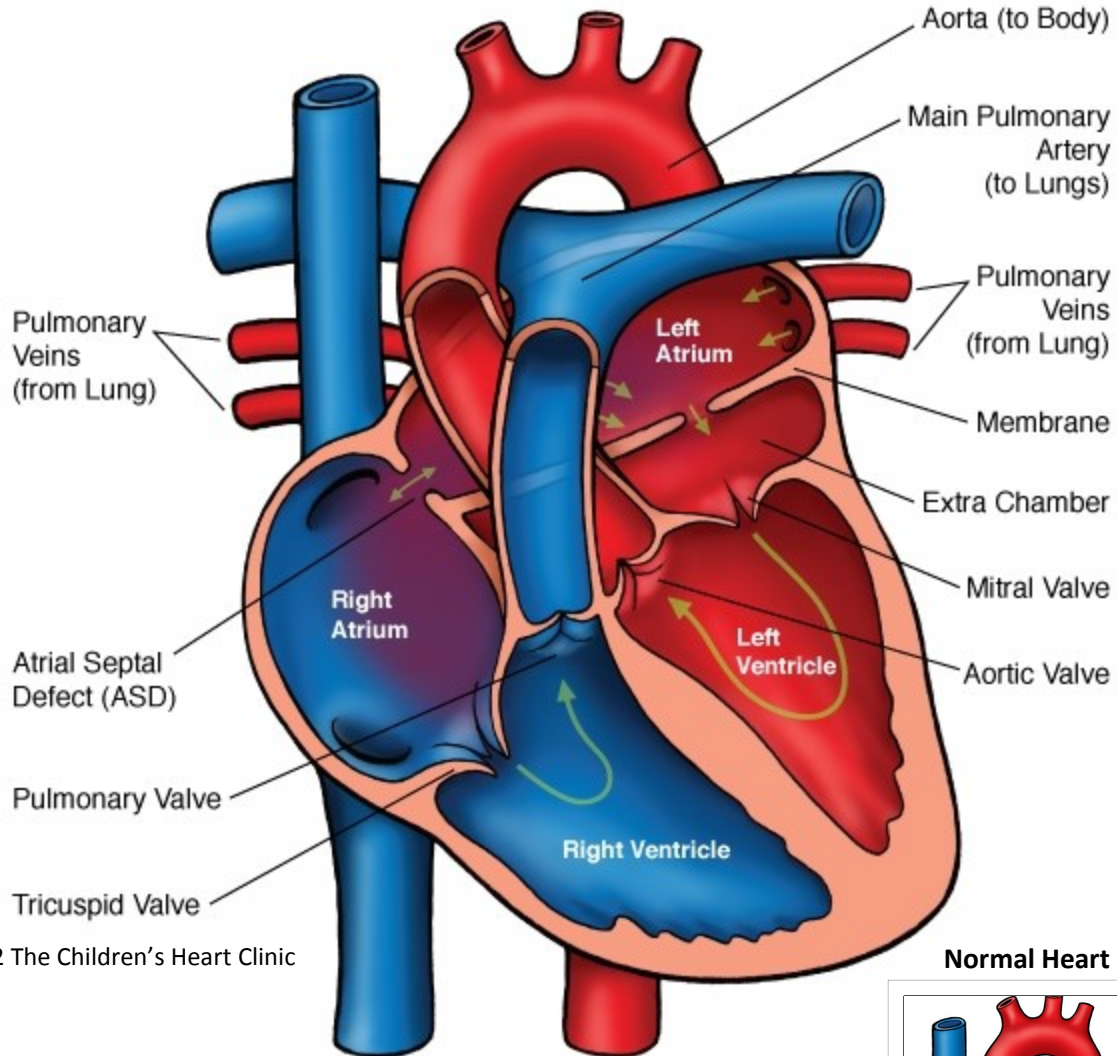
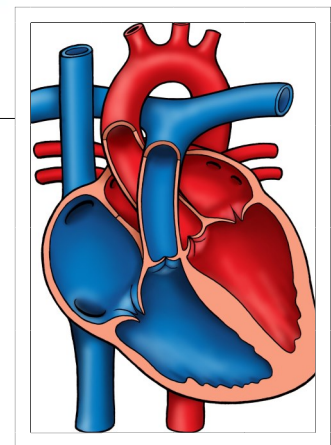


Cor Triatriatum



© 2012 The Children's Heart Clinic

Normal Heart



NOTES:

Children's Heart Clinic, P.A., 2530 Chicago Avenue S, Ste 500, Minneapolis, MN 55404
 West Metro: 612-813-8800 * East Metro: 651-220-8800 * Toll Free: 1-800-938-0301 * Fax: 612-813-8825
 Children's Minnesota, 2525 Chicago Avenue S, Minneapolis, MN 55404
 West Metro: 612-813-6000 * East Metro: 651-220-6000

Cor Triatriatum

In the normal heart, there are two atria, right and left. The right atrium pumps blood through the tricuspid valve to the right ventricle. The blood then leaves the right ventricle through the pulmonary artery to the lungs for oxygenation. Blood returns to the left atrium by way of the pulmonary veins. The oxygenated blood then travels to the left ventricle through the mitral valve and out to the body through the aorta.

In Cor triatriatum, the left atrium is divided into two chambers by a fibromuscular membrane with an opening. This division of the left atrium results in three total atria (2 left, 1 right). The pulmonary veins drain abnormally into this second left atrial chamber, creating varying degrees of obstruction to pulmonary venous return. As a result, pulmonary artery and pulmonary venous hypertension (abnormally high pressures) occur, similar to patients with mitral stenosis. This is a very rare congenital cardiac anomaly occurring in 0.5-1% of all congenital heart defects, and is often associated with other congenital cardiac anomalies, such as partial or total anomalous pulmonary venous return.

Physical Exam/Symptoms:

- Dyspnea (difficulty breathing).
- Crackles in the lungs.
- Grade III systolic murmur.
- Congestive heart failure: tachypnea (fast breathing), poor growth/feeding, cardiomegaly (enlarged heart).

Diagnostics:

- Chest X-ray: Pulmonary venous congestion/edema (wet appearance to the lungs), prominent main pulmonary artery, right-sided heart enlargement.
- EKG: Right axis deviation and severe right ventricular hypertrophy.
- Echocardiogram: Diagnostic.

Medical Management/Treatment:

- Diuretics are used in the short term to manage pulmonary congestion/edema and decrease work of breathing.
- If arrhythmias/atrial fibrillation occur, anticoagulation with heparin or coumadin may be needed.
- Surgical correction is *always* indicated. This involves removal of the accessory fibromuscular membrane and closure of the atrial communication with a patch of the child's own pericardium (sac that surrounds the heart).
- Your child will require life-long cardiology follow-up.

Long-term Outcomes:

- Pulmonary hypertension usually improves rapidly if surgical correction occurs early.
- High survival rate post-repair.
- Atrial arrhythmias may occur postoperatively or later in life. Medications or a cardiac catheterization procedure called an ablation may be needed to treat/control arrhythmias.
- Growth and development post-repair are usually normal in the absence of other congenital heart disease or co-morbidities.