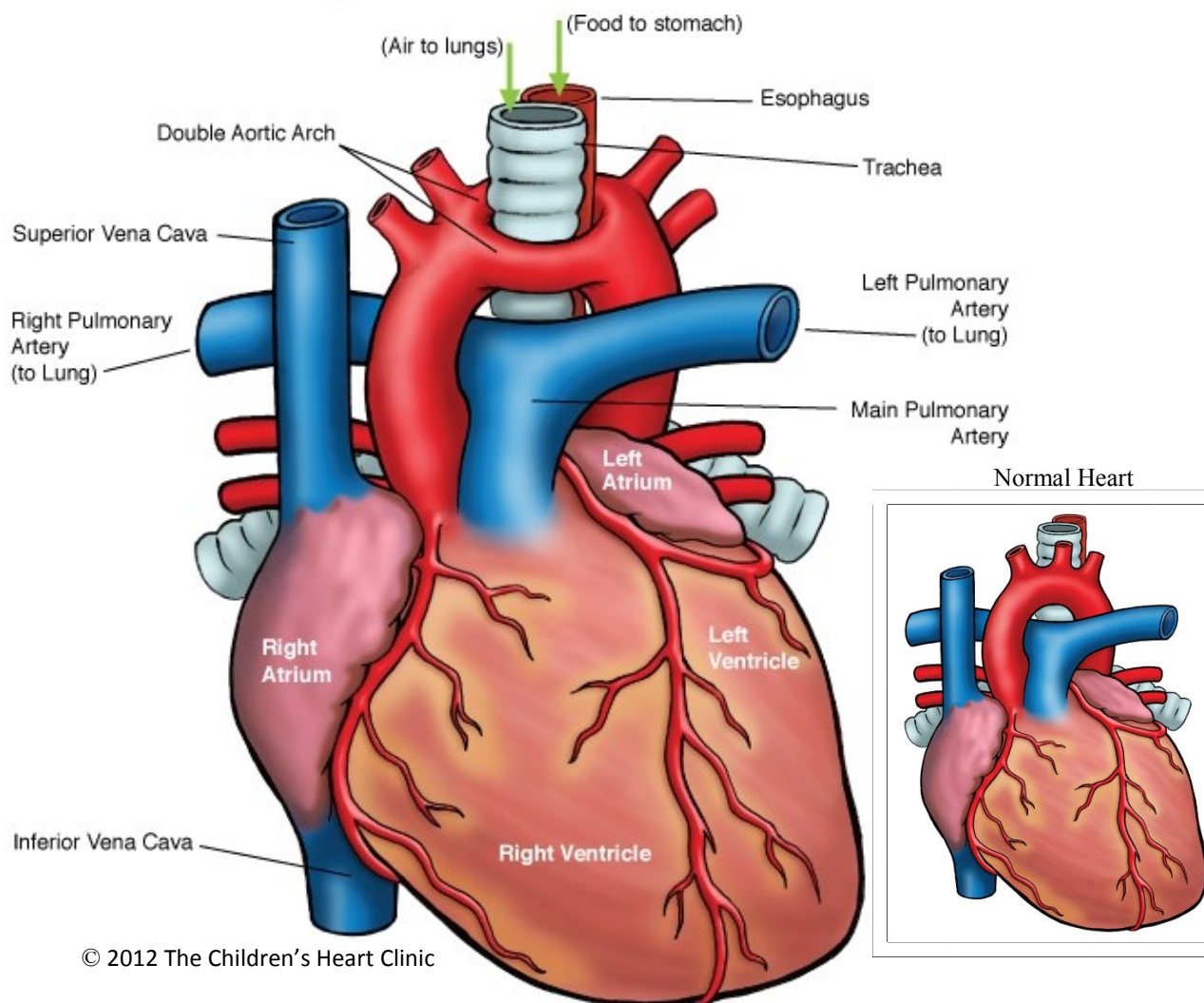


Vascular Ring - Double Aortic Arch



NOTES:

Children's Heart Clinic, P.A., 2530 Chicago Avenue S, Ste 500, Minneapolis, MN 55404
 West Metro: 612-813-8800 * East Metro: 651-220-8800 * Toll Free: 1-800-938-0301 * Fax: 612-813-8825
 Children's Minnesota, 2525 Chicago Avenue S, Minneapolis, MN 55404
 West Metro: 612-813-6000 * East Metro: 651-220-6000

Vascular Ring

Vascular ring is a type of congenital heart disease where abnormalities of the aortic arch or rarely, the pulmonary artery (PA), result in respiratory symptoms or feeding problems due to compression or obstruction of the airway or esophagus. The fetal heart starts with two symmetrical branches of the aorta. Parts of the aortic arch regress in the second month of fetal life, usually resulting in a left aortic arch with three artery branches: the innominate artery, the left common carotid artery, and the left subclavian artery. The ductus arteriosus is present from the left pulmonary artery to the aorta, near the left subclavian origin. Vascular rings occur when there is abnormal regression of parts of the original two aortic arch branches.

Vascular rings are either complete or incomplete. Complete vascular ring describes abnormalities of the aorta or pulmonary arteries that form a complete circle around the esophagus and trachea. Incomplete vascular rings compress the esophagus and trachea, but do not form a complete circle around them. Vascular rings occur in less than 1% of children with congenital heart disease. There are several types of vascular rings. The two most common types of vascular ring are described below.

Types:

- **Double Aortic Arch:** A left and a right aortic arch are present, resulting in a complete circle around the trachea and esophagus. The right aortic arch is usually larger than the left aortic arch. The right arch gives rise to the right common carotid artery and right subclavian artery and the left arch gives rise to the left common carotid artery and left subclavian artery. Double aortic arch is the most common type, occurring in 40% of children with vascular ring.
- **Right Aortic Arch with Left Ligamentum Arteriosum:** In this type, the left subclavian artery abnormally originates from the descending aorta and courses behind the esophagus and the ligamentum connects the left pulmonary artery and the descending aorta together. This type also forms a complete circle around the esophagus and trachea. Notably, 25% of patients with cyanotic heart disease with a right aortic arch have a left ligamentum arteriosum. Right aortic arch with left ligamentum arteriosum is the second most common type, occurring in 30% of children with vascular ring.

Physical Exam/Symptoms:

- Many infants and children are asymptomatic.
- Children with double aortic arch tend to have symptoms sooner and in greater severity than children with right aortic arch with left ligamentum arteriosum.
- Inspiratory stridor and feeding problems occur in infancy.
- History of pneumonia is common.
- Cardiac exam is normal, unless other congenital heart disease is present.
- Respiratory symptoms may worsen while feeding or in the setting of respiratory infections.
- Older children may describe food getting “stuck” as they swallow or have frequent coughing/choking while eating.

Diagnostics:

- **Barium esophagram:** Diagnostic. Barium (contrast) fluid is consumed by mouth and coats the esophagus. Fluoroscopy (x-ray) is done at the same time the barium is consumed, which reveals compression or obstruction of the esophagus.
- **Cardiac Computed Tomography (CT) or Magnetic Resonance Imaging (MRI):** Used to diagnose aortic arch and pulmonary artery abnormalities.
- **Echocardiogram:** Helpful in confirming diagnosis of vascular ring and diagnosis of other congenital heart disease, if present.

Medical Management/Treatment:

- Children with vascular rings that are asymptomatic do not require surgical intervention.
- Infants and children with mild symptoms require careful feeding practices and prompt evaluation and treatment of respiratory infections.

Vascular Ring

- Timing of surgical intervention is determined by the severity of associated symptoms.
- Children need careful respiratory management in the postoperative period.

Long-Term Outcomes:

- If respiratory symptoms were severe preoperatively, it may take up to a year for noisy breathing to resolve.
- Surgical mortality is nearly zero.
- Normal life expectancy and development for children without other congenital anomalies.
- Routine cardiology follow up for 5 years post-surgical repair if your child does not have other cardiac disease.