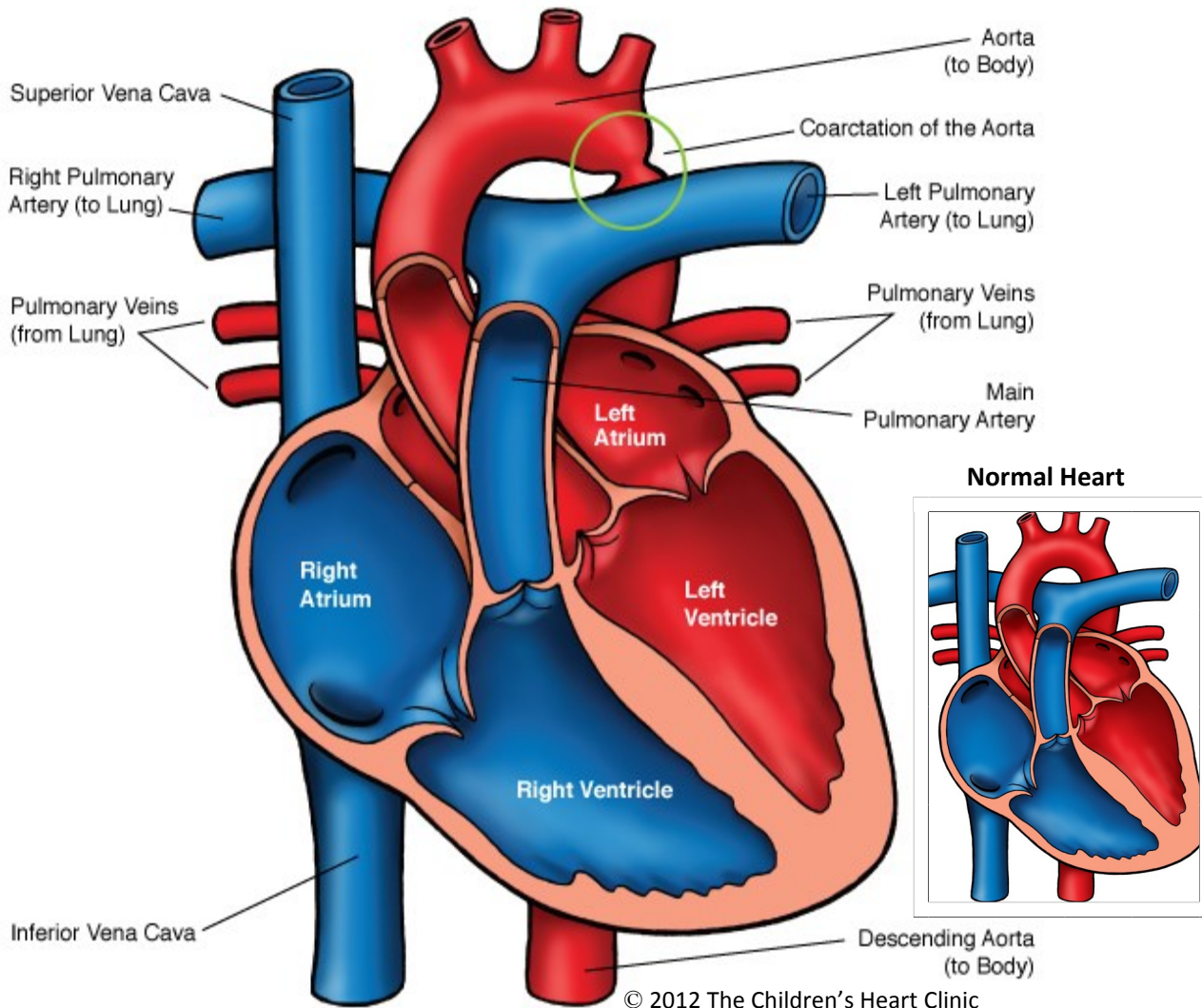


Coarctation of the Aorta



NOTES:

Children's Heart Clinic, P.A., 2530 Chicago Avenue S, Ste 500, Minneapolis, MN 55404
West Metro: 612-813-8800 * East Metro: 651-220-8800 * Toll Free: 1-800-938-0301 * Fax: 612-813-8825
Children's Minnesota, 2525 Chicago Avenue S, Minneapolis, MN 55404
West Metro: 612-813-6000 * East Metro: 651-220-6000

Coarctation of the Aorta (CoA)

Coarctation of the aorta (CoA) refers to narrowing of the aorta. This narrowing may be discrete or long-segment and vary in severity. CoA occurs in 8-10% of all congenital heart defects and is often associated with other cardiac lesions such as aortic hypoplasia, abnormalities of the aortic valve, ventricular septal defects (VSD), and mitral valve anomalies. CoA occurs more commonly in males than females (ratio 2:1). 30% of patients with Turner's syndrome have CoA.

In *symptomatic* infants, the descending aorta is supplied mostly by right to left blood flow through the ductus arteriosus during fetal life and at birth. Symptomatic infants often have associated cardiac anomalies present. As ductus arteriosus closes hours to days after birth, blood flow to the body is compromised. In *asymptomatic* infants and children with CoA, the descending aorta is supplied by a normal amount of blood flow from the aortic isthmus and ductus arteriosus. Other cardiac anomalies are often not present (with the exception of bicuspid aortic valve). Adequate collateral circulation may develop between the proximal and distal aorta.

Physical Exam/Symptoms:

- *Symptomatic infants:*
 - Poor feeding, poor weight gain, tachypnea (fast breathing), or signs of shock (pale, poor urine output, acidosis, weak peripheral pulses) develop in the first 6 weeks of life as the ductus arteriosus closes and blood flow to the body is compromised.
 - Loud gallop is usually present. A systolic ejection murmur heard over the precordium may be present, though 50% of patients have no murmur.
- *Asymptomatic infants and children:*
 - Pulses in the lower extremities are weak or absent.
 - Normal growth and development is typical.
 - Blood pressure in the legs is equal or lower to blood pressure in the arms.
 - Arm blood pressure is usually elevated (hypertension).
 - Systolic thrill may be present at the suprasternal notch. A systolic ejection murmur is often heard at the upper right sternal border and middle left sternal border and radiates to the back.

Diagnostics:

- Chest X-ray: In *symptomatic* infants, marked cardiomegaly (enlarged heart) and pulmonary edema are often present. In *asymptomatic* infants and children, heart size is often normal. Dilatation of the ascending aorta may be seen.
- EKG: Right ventricular hypertrophy (RVH) or right bundle branch block (RBBB) present in neonates. Older children have left ventricular hypertrophy (LVH).
- Echocardiogram: Diagnostic.

Medical Management/Treatment:

- Life-long cardiology follow up is needed, regardless of type and timing of repair.

Symptomatic:

- Prostaglandin therapy started as soon as possible to keep ductus open.
- Surgical repair as a neonate is warranted (see Coarctation Repair).

Asymptomatic:

- Hypertension management/monitoring
- Balloon angioplasty, stent placement, or surgical repair (see Coarctation Repair).
- Bacterial endocarditis prophylaxis

Long-Term Outcomes:

- Mortality rate <5%
 - Residual obstruction or re-coarctation may occur in up to 30% of all children after balloon angioplasty or surgical repair. Recurrence rate is lower following surgical repair than after balloon angioplasty.
 - Bacterial endocarditis prophylaxis prior to dental procedures for children with valve abnormalities or residual coarctation.
 - Hypertension (high blood pressure) may persist post-repair, requiring medicines to control.
 - Life expectancy is normal in the absence of other cardiac anomalies or co-morbidities.
-