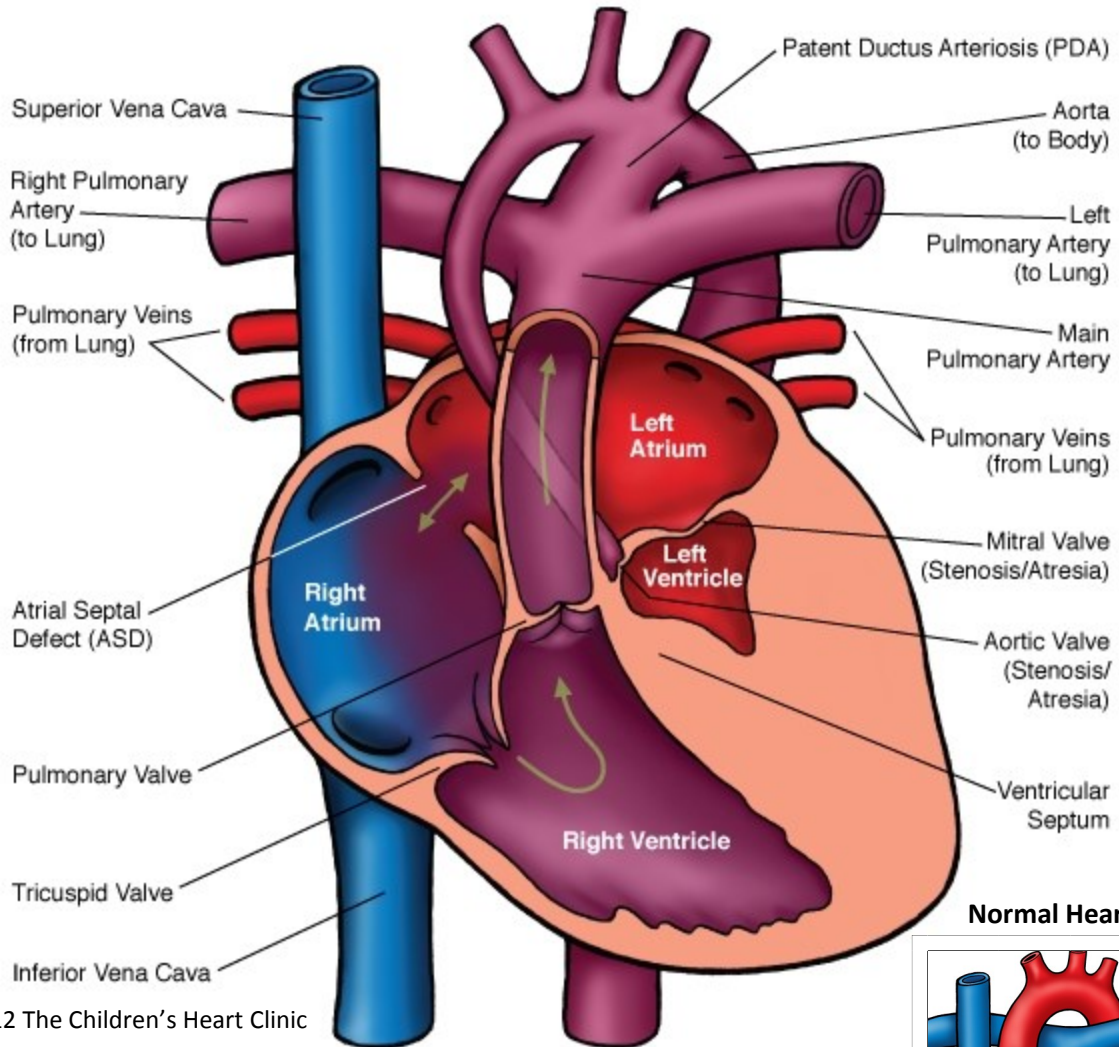


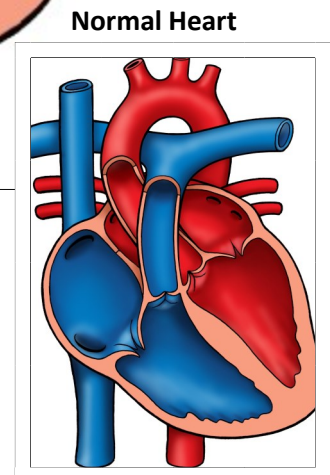
## Hypoplastic Left Heart Syndrome (HLHS)



© 2012 The Children's Heart Clinic



### NOTES:



Children's Heart Clinic, P.A., 2530 Chicago Avenue S, Ste 500, Minneapolis, MN 55404  
 West Metro: 612-813-8800 \* East Metro: 651-220-8800 \* Toll Free: 1-800-938-0301 \* Fax: 612-813-8825  
 Children's Minnesota, 2525 Chicago Avenue S, Minneapolis, MN 55404  
 West Metro: 612-813-6000 \* East Metro: 651-220-6000

---

## Hypoplastic Left Heart Syndrome (HLHS)

In the normal heart, there are two atria and two ventricles. Blood comes back from the body from the superior vena cava (SVC) and inferior vena cava (IVC) to the right atrium through the tricuspid valve to the right ventricle. The ventricle contracts and blood is pumped through the pulmonary valve to the pulmonary arteries out to the lungs where the blood is oxygenated. Blood returns from the lungs by the pulmonary veins to the left atrium. It then travels from the left atrium through the mitral valve to the left ventricle. The left ventricle contracts, sending blood through the aortic valve through the aorta and out to the body.

Hypoplastic left heart syndrome (HLHS) refers to several closely related anomalies. The left ventricle (LV) is hypoplastic (small and underdeveloped) and nonfunctional, which means the right ventricle must serve as the single pumping chamber. There is critical stenosis (narrowing) or atresia (absence) of the mitral and/or aortic valves and hypoplasia of the ascending aorta and aortic arch. Coarctation of the aorta (COA) occurs in 75% of patients with HLHS and ventricular septal defects (VSD) occur in 10%. HLHS occurs in 8% of all children with congenital heart defects.

### Physical Exam/Symptoms:

- Tachycardia (fast heart rate), dyspnea (difficulty breathing), pulmonary crackles, weak peripheral pulses, and vasoconstriction are common within a few hours of life.
- S2 is loud and single and a gallop rhythm is present. There is usually no heart murmur.
- Congestive heart failure (CHF) develops with hepatomegaly (enlarged liver).
- Oxygen saturations are usually 90% or lower shortly after birth and do not improve with supplemental oxygen.

### Diagnostics:

- Chest X-ray: Moderate to severe cardiomegaly (heart enlargement) and pulmonary venous congestion are present.
- EKG: Demonstrates right ventricular hypertrophy (RVH).
- Echocardiogram: Diagnostic. Aids in determining if there is a need for cardiac catheterization and angiography prior to surgery.
- Cardiac Catheterization: Helpful in evaluating the pressures in the heart. Cardiac catheterization is often performed prior to the second and third palliative surgeries and/or if additional interventions such as ballooning or stenting of the pulmonary artery (PA) or coiling of collateral vessels.

### Medical Management/Treatment:

- For infants who are diagnosed with HLHS in utero, it is recommended that delivery take place in a tertiary care hospital with transfer to Neonatal Intensive Care Unit as soon as possible to initiate cardiology evaluation and medical interventions.
- Prostaglandin E (PGE) therapy should be started as soon as possible after birth to keep the ductus arteriosus patent, as this is the baby's only source of blood flow to the body and vital organs.
- Intubation and mechanical ventilation may be necessary prior to surgery.
- Balloon atrial septostomy for neonates without an adequate atrial septal communication may help improve oxygenation and decompress the left atrium prior to surgery. This is usually done in the cardiac catheterization lab.
- Surgical repair is necessary for survival in several stages. The first surgery is done within the first week of life (see Norwood procedure). The bidirectional Glenn procedure is performed between 4-6 months of age and the modified Fontan procedure between 2-4 years of age.
- Cardiac transplantation is considered for some patients with physiology not amenable to staged repair.
- Life-long anticoagulation to prevent thrombus (clot formation) is recommended (i.e. coumadin, aspirin).
- Arrhythmias may develop over time, necessitating medical therapy or pacemaker placement.
- Life-long cardiology follow-up is needed.

---

## Hypoplastic Left Heart Syndrome (HLHS)

### Long-Term Outcomes:

- Neonates who do not undergo surgical repair or receive a transplant do not survive.
- Survival through first stage palliation is greater than 95% and 5-10 year survival following Fontan palliation is 80-85%
- Children with HLHS should be active and treated like every other child with a few special considerations:
  - Exercise tolerance/stamina is often limited in comparison to children with two ventricle hearts and participation in competitive contact sports is not recommended.
  - Temperature and altitude extremes are often poorly tolerated.
  - Growth and developmental outcomes vary and are impacted by the presence or absence of other co-morbidities, including ADHD.