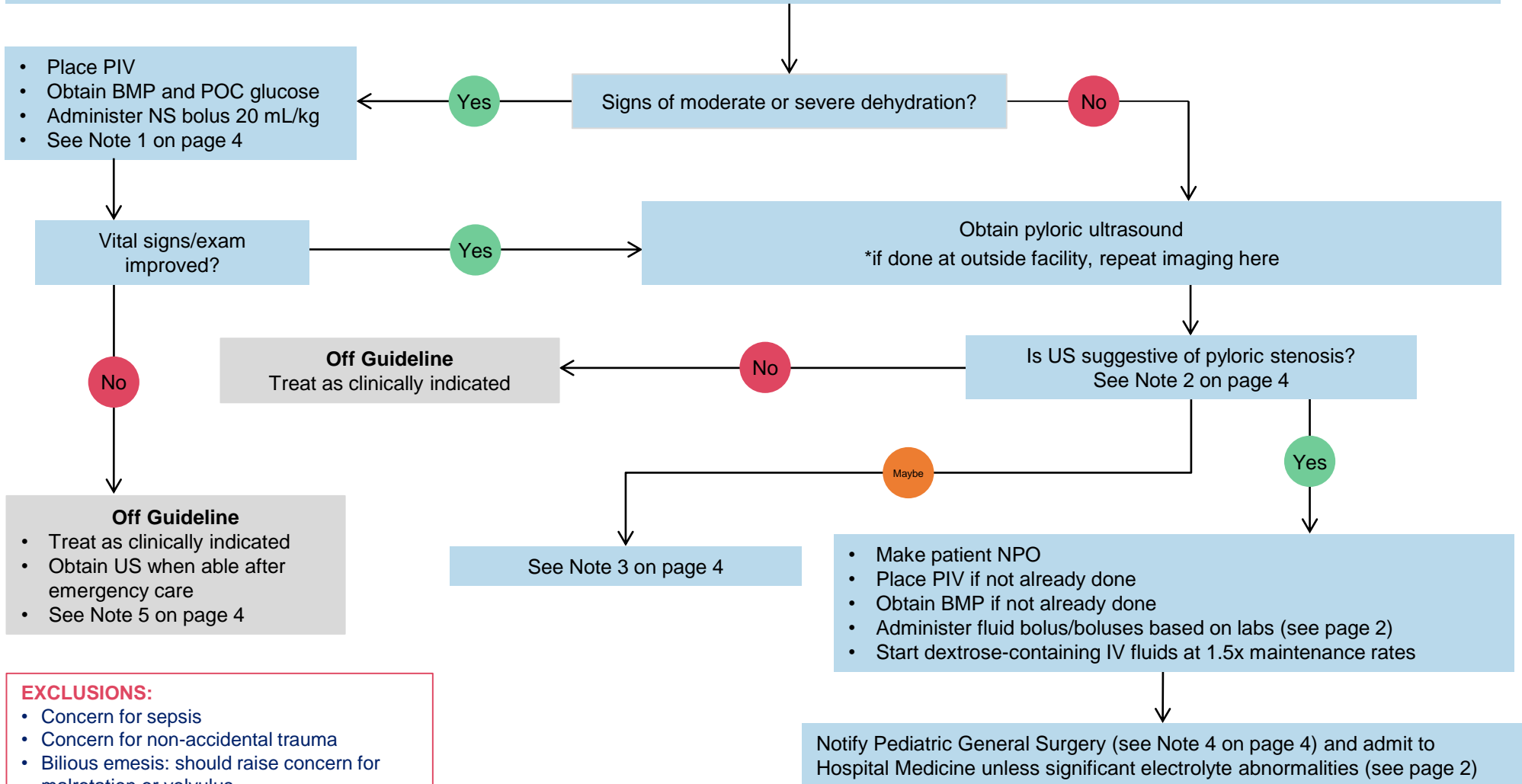


Aim: To standardize evaluation and management of patients with suspected pyloric stenosis

Patient presents to the ED with signs or symptoms of pyloric stenosis:

Progressive non bilious vomiting, projectile emesis, hungry after vomiting, weight loss despite good appetite, palpable "olive" like mass in mid epigastrium



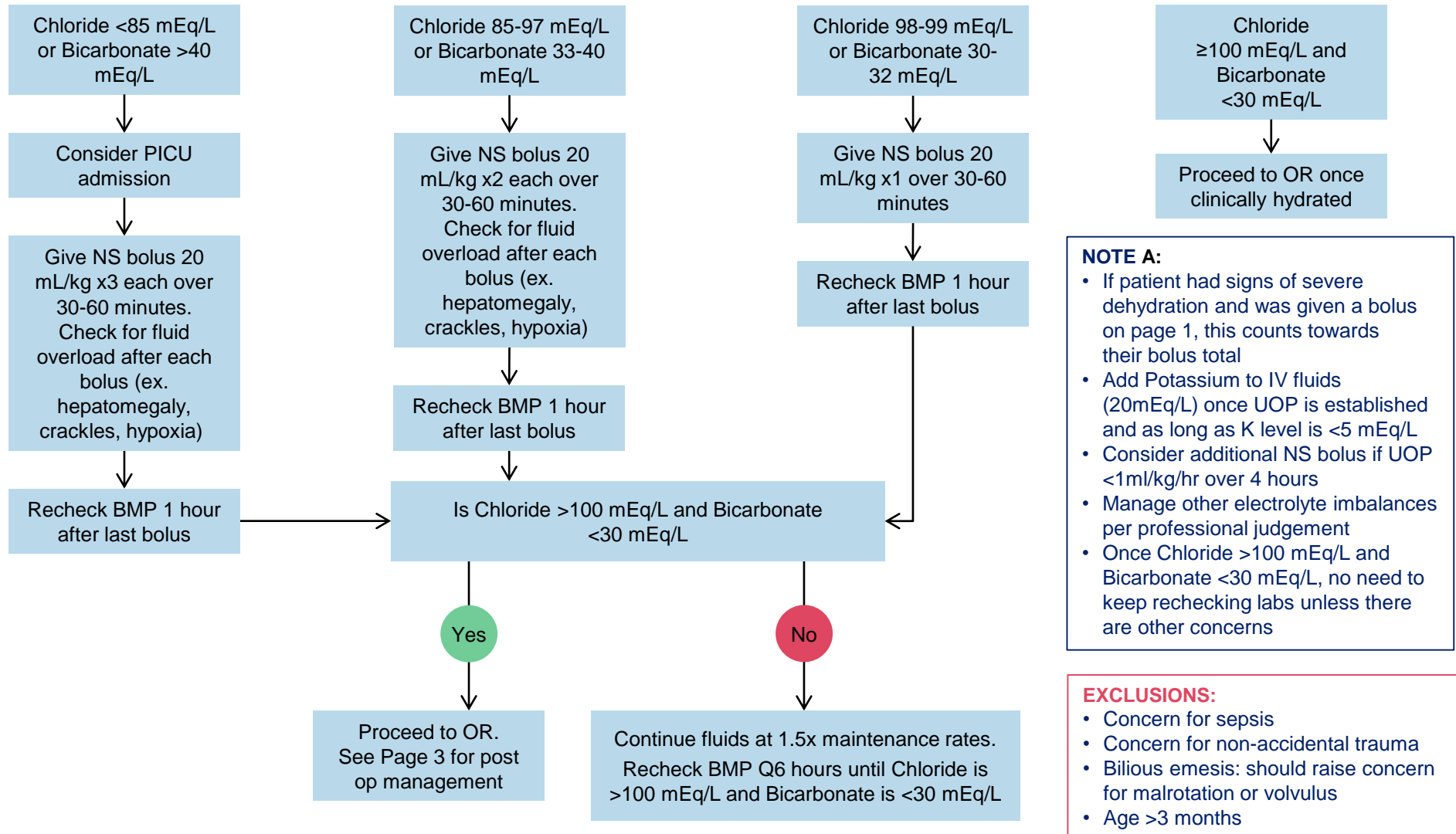
EXCLUSIONS:

- Concern for sepsis
- Concern for non-accidental trauma
- Bilious emesis: should raise concern for malrotation or volvulus
- Age < 2 weeks or >3 months

Aim: To standardize evaluation and management of patients with suspected pyloric stenosis

Review BMP:

See Note 1 on page 4 and Note A on this page



NOTE A:

- If patient had signs of severe dehydration and was given a bolus on page 1, this counts towards their bolus total
- Add Potassium to IV fluids (20mEq/L) once UOP is established and as long as K level is <5 mEq/L
- Consider additional NS bolus if UOP <1ml/kg/hr over 4 hours
- Manage other electrolyte imbalances per professional judgement
- Once Chloride >100 mEq/L and Bicarbonate <30 mEq/L, no need to keep rechecking labs unless there are other concerns

EXCLUSIONS:

- Concern for sepsis
- Concern for non-accidental trauma
- Bilious emesis: should raise concern for malrotation or volvulus
- Age >3 months

Aim: To standardize evaluation and management of patients with suspected pyloric stenosis

Post Op Management:

1. Decrease IV fluids to maintenance rate once back to the unit
2. NPO until recovered from anesthesia
3. Once awake, ok to trial formula or breastmilk per home routine (see Note 6)
4. Acetaminophen (Tylenol®) as needed for pain
5. Saline lock IV once tolerating oral feeds

Discharge Criteria:

1. Completed post anesthesia monitoring per Children's Guideline (see Note 7)
2. Tolerating appropriate PO- minimum of 2 feeds in a row without large emesis
3. Voiding
4. Pain controlled
5. No fever

Follow Up:

1. Follow up with primary care provider in 3-7 days for weight check
2. Follow up with pediatric general surgery as needed

Aim: To standardize evaluation and management of patients with suspected pyloric stenosis

NOTES:

Note 1: Labs can be normal in patients who are diagnosed early, but labs that are supportive of diagnosis include: hypokalemia (if longer period of vomiting), hypochloremic metabolic alkalosis with low chloride and elevated bicarbonate (from loss of gastric acid). We don't recommend routinely obtaining a CBC, which is expected to be normal in uncomplicated hypertrophic pyloric stenosis. If obtained, abnormal results should raise the suspicion for alternate reasons for vomiting.

Note 2: Pyloric ultrasonography is considered positive when muscle thickness is greater than 3 mm and channel length is 15mm or more.

Note 3: If pyloric ultrasound is equivocal consider: discussion with general surgery, admission for observation, repeat US in 48 hours and/or upper GI if suspicion is high but initial US is not diagnostic. Upper GI findings suggestive of pyloric stenosis: narrowing of the canal or pointing of the barium at the pyloric canal.

Note 4: Call General Surgery between 6am and 10pm; otherwise, day team to call at 6am.

Note 5: In infants who are severely dehydrated or ill appearing, consider alternative diagnoses such as sepsis, intestinal obstruction, or a primary metabolic disorder. Other differential diagnoses to consider for an infant with persistent vomiting includes, but is not limited to: gastroesophageal reflux, food allergy or FPIES, gastric or duodenal inflammatory disease, liver disease, toxin exposure, UTI, pneumonia, pancreatic disease or testicular/ovarian torsion. May still be appropriate to obtain a pyloric ultrasound in these cases.

Note 6: If large volume emesis x2, consider modifying ad lib feeding plan with: Pedialyte 30 mL Q2 hours x2, then breast milk/formula 30 mL Q2 hours x2, then back to ad lib.

Note 7: Refer to [Post Sedation Infant Monitoring](#)

REFERENCES:

1. Cruz-Centeno, Neimar; Fraser, James A. MD; Stewart, Shai MD; Marlor, Derek; Rentea, Rebecca M.; Aguayo, Pablo; Juang, David; Hendrickson, Richard J.; Snyder, Charles L.; St.Peter, Shawn D.; Fraser, Jason D.; and Oyetunji, Tolulope A., "Hypertrophic Pyloric Stenosis Protocol: A Single Center Study" (2023). Presentations. 78. <https://scholarlyexchange.childrensmercy.org/presentations/78>
2. Dalton Brian G.A. Optimizing fluid resuscitation in hypertrophic pyloric stenosis. Journal of Pediatric Surgery 2016 51(8):1279-1282. Doi:10.1016/j.jpedsurg.2016.01.013
3. Dellinger, M., Clogston, M., Fenstermacher, S., Foster, C., Hrachovec, J., Meyer, I., Migita, R., Morton, J., Ojo, B., Oldroyd, K., Otto, R., Test, M., & Migita, D. (2024, July 22). Pyloric stenosis pathway. Seattle Children's, Center for Quality and Patient Safety. <https://www.seattlechildrens.org/pdf/pyloric-stenosis-pathway.pdf>
4. Endom, E., Dorfman, S. & Olive, A. Infantile Hypertrophic Pyloric Stenosis. Up to Date. November 2024. Retrieved from [Infantile hypertrophic pyloric stenosis – UpToDate](#)
5. Fraiser, J, Osuchukwu, O., Briggs, K.B., et al. Evaluation of a fluid resuscitation protocol for patients with hypertrophic pyloric stenosis. Journal of Pediatric Surgery 57 (2022) 386-389. Doi.org/10.1016/j.jpedsrug.2021.10.052
6. Hypertrophic Pyloric Stenosis / Pyloromyotomy Care Guideline. Children's Hospital of Orange County, 2017. Retrieved from: [PyloricStenosisCareGuideline.pdf](#)
7. Kamata, M., Cartabuke, R.S. & Tobia, J.D. Perioperative care of infants with pyloric stenosis. Pediatric Anesthesia 25(2015) 1193-1206. Doi:10.1111/pan.12792
8. Noffsinger, D., Diefenbach, K., Halaweish, I., Kenney, B. Gonzalez, D., et al. CPP-ED-IP-Surgery Pyloric Stenosis Clinical Pathway. December, 2021. Retrieved from [Clinical Pathway: Pyloric Stenosis](#)
9. Pyloric Stenosis: Clinical Practice Guideline. Children's Hospital at Vanderbilt. June 2023. Retrieved at [Pyloric Stenosis CPG_06.20.23.pdf](#)
10. Rich, B. and Dolgin, S. Hypertrophic Pyloric Stenosis. Pediatric Review (2021) 42 (10): 539-545. Doi.org/10.1542/pir.2020-003277
11. Wroe, Tiffany, APRN, Chandler, MD. Johns Hopkins All Children's Hospital Pyloric Stenosis Clinical Pathway. June 2021. Retrieved from [pyloric-stenosis-6_1_2021.pdf](#)

WORKGROUP:

Jodi O'Neill, APRN- CNP Hospital Medicine
Joshua Short, MD, Pediatric General Surgery
Sara Bryan, APRN- CNP Pediatric General Surgery
Susan Johnson, APRN-CNP Pediatric General Surgery
Nadia Maccabee-Ryaboy, MD Hospital Medicine
Benjamin Kloesel, MD Anesthesia
Nihal Hamouda, MD Emergency Medicine